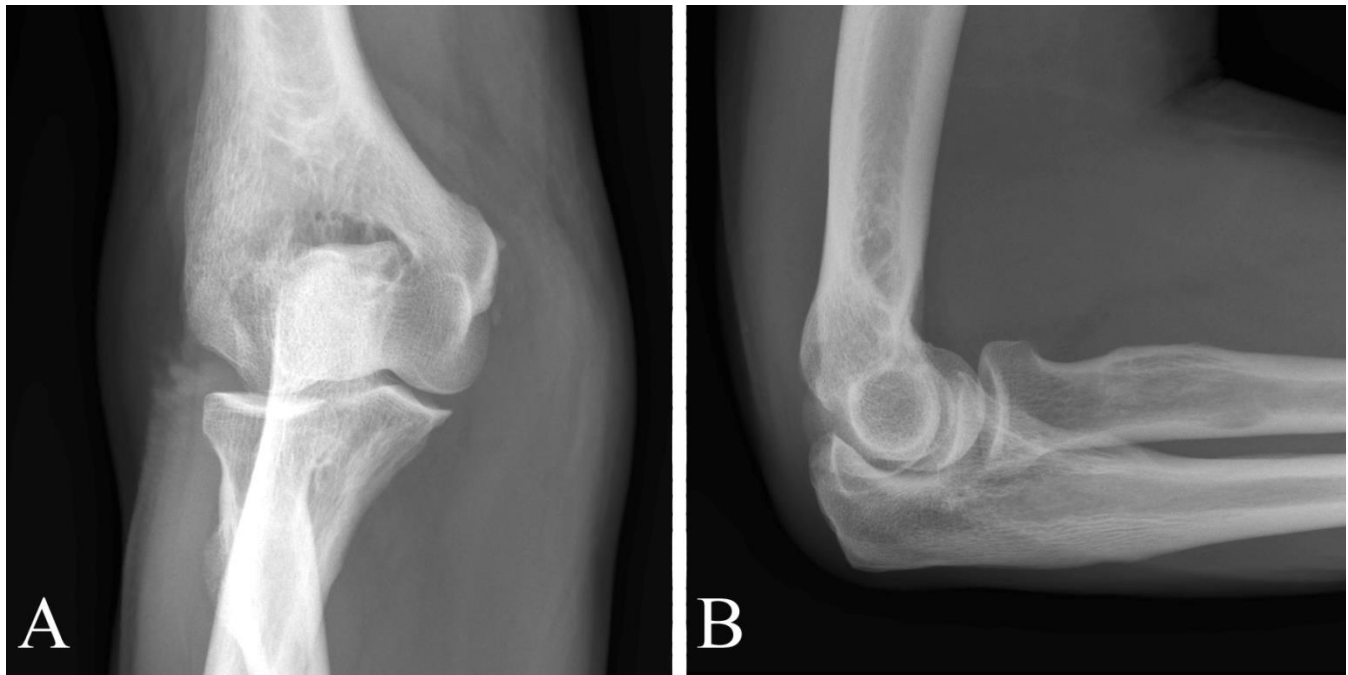


CLINICAL PRESENTATION AND RADIOLOGY QUIZ QUESTION

A 66 year old man presents with a one month history of elbow pain. He sustained an injury using a shearing device approximately one month prior to coming into the clinic. The patient felt something snap in his elbow and had acute elbow pain. However, this pain subsided over the next few hours and the patient was doing better until he opened a door the day before coming to the clinic (one month following the initial injury), at which time he had recurrent elbow pain. On physical examination, the patient has pain along the distal biceps tendon with no gross bicep deformity. He has full range of elbow motion, with some discomfort with supination/pronation. There is no tenderness along the medial or lateral epicondyle. Neurovascular examination is unremarkable. A plain film of the elbow was obtained (the study included bilateral oblique views in addition to the anteroposterior (AP) and lateral views shown here):



Which of the following imaging studies is the next examination of choice for evaluation of persistent elbow pain?

- (a) computed tomography (CT) of the elbow
- (b) magnetic resonance (MR) imaging of the elbow
- (c) nuclear medicine bone scan of the elbow
- (d) ultrasound (US) examination of the elbow

RADIOLOGY QUIZ QUESTION, ANSWER, AND EXPLANATION

Which of the following imaging studies is the next examination of choice for evaluation of persistent elbow pain?

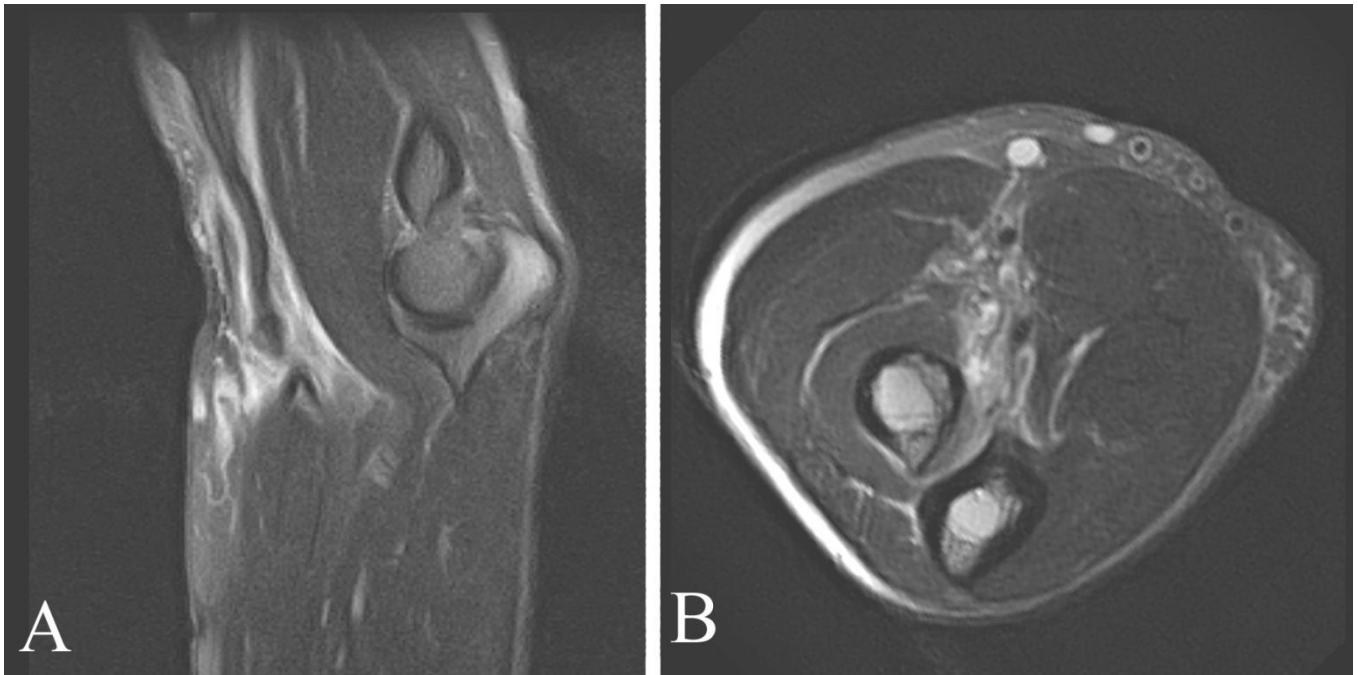
- (a) computed tomography (CT) of the elbow
- (b) magnetic resonance (MR) imaging of the elbow
- (c) nuclear medicine bone scan of the elbow
- (d) ultrasound (US) examination of the elbow

The initial imaging study in almost all patients with chronic elbow pain is a plain film examination of the elbow, which was obtained. This was normal (see image on Page 1). Given the patient's symptoms, possible diagnoses include occult fracture (unlikely given the full range of motion) and soft tissue injury including biceps tendon rupture. Generally, MR imaging of the elbow (b) is the next imaging study performed.

CT of the elbow (a) is usually done to delineate the configuration of a known fracture or fracture/dislocation, or following arthrography to depict the collateral ligaments if MR cannot be performed (because of, for example, a pacer or aneurysm clip). However, CT is not the best next step in this patient, and (a) is incorrect. A nuclear medicine bone scan (c) may be helpful in excluding areas of increased radiotracer indicating increased bone turnover such as might be seen in metastatic deposit or stress fracture. However, nuclear medicine is typically performed only *after* magnetic resonance imaging of the shoulder, and (b) is incorrect. US examination of the elbow may help demonstrate an effusion, but is generally not helpful in evaluation of other abnormalities which may cause pain following trauma, and (d) is incorrect.

IMAGING STUDY AND QUESTIONS

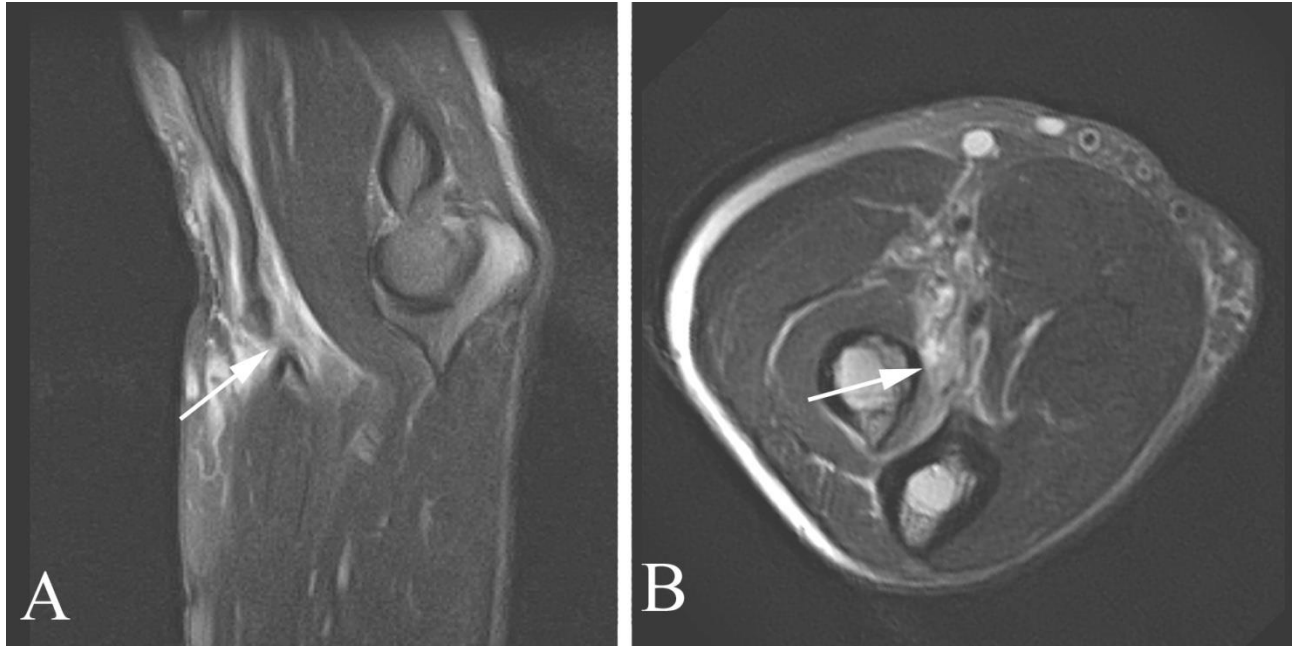
The patient's primary care provider referred the patient to an orthopedic surgeon. The patient's history and physical examination findings were equivocal. The patient had focal pain in the elbow along the course of the biceps tendon without pain along the epicondyles and had a good and mostly pain-free range of motion of the elbow. An imaging study was performed:



Imaging questions:

- 1) What type of study is shown?
- 2) Are there any abnormalities?
- 3) What is the most likely diagnosis?
- 4) What is the next step in management?

IMAGING STUDY QUESTIONS AND ANSWER



Imaging questions:

- 1) What type of study is shown? Sagittal (A) and axial (B) elbow magnetic resonance study.
- 2) Are there any abnormalities? Yes. There is a full thickness defect in the distal biceps tendon, see in A at the location of the arrow. In B, there is no tendon along the expected distal course including at the insertion on the radial tuberosity (arrow).
- 3) What is the most likely diagnosis? Biceps tendon rupture.
- 4) What is the next step in management? Counsel the patient regarding the options of leaving the tear (with likely gradually diminishing pain and loss of function) versus biceps tendon repair.

PATIENT DISPOSITION, DIAGNOSIS, AND FOLLOW-UP
--

The patient underwent a repair of the biceps tendon rupture (a full thickness tear was found at surgery) and had a good outcome with, following healing and physical therapy, elimination of elbow pain and excellent function.

SUMMARY

Presenting symptoms: The patient presented recurrent elbow pain. Considerations in patients with recurrent and chronic elbow pain include referred pain from outside the elbow (for example, referred neck or shoulder pain or radicular pain), radiohumeral arthritis, medial or lateral epicondylitis, fracture (in the setting of trauma), collateral ligament tear, neuritis, biceps and triceps tendon tear or tendinopathy, anterior capsule strain, and osteochondritis desiccans of the capitellum.

Imaging work-up: The initial imaging study of choice for acute or recurrent elbow pain is a plain film examination of the elbow. Most patients with chronic elbow pain probably do not require *any* imaging, but if imaging is performed, plain film evaluation is the best first step. Plain film examination is useful to exclude fracture, calcifications along the epicondyles (seen in epicondylitis), to demonstrate degenerative changes, and to exclude large destructive tumors. In difficult cases (such as the one presented here), further imaging may be required because of a conflict between the patient's symptoms and physical examination findings, or to firmly document pathology prior to surgery. In most cases, the next imaging study of choice is MR imaging. MR of the elbow is typically performed without intra-articular injection of contrast material; note, however, that in athletes, particularly baseball pitchers, intra-articular contrast is very helpful to evaluate the collateral ligaments.

Establishing the diagnosis: Biceps tendon tear at the elbow can usually be diagnosed on the basis of a typical history and physical examination, but in some cases (such as this one) physical examination findings (even when the physical examination is performed by an expert) are equivocal. This may follow from either a small sliver of the tendon being intact, or because of the tendon being held in place by peritendinous tissue. The reference standard for tendon tear is typically what is found in the operating room.

Take-home message: The initial study of choice for virtually all patients with recurrent or chronic elbow pain (when imaging is needed) is a plain film evaluation. In patients who require additional imaging, MR is generally the next imaging study of choice.

FURTHER READING

Anderson BC, Anderson RJ. Evaluation of elbow pain in adults. UpToDate, accessed 11/6/09. This discussion is about nontraumatic elbow pain.

Chorley J. Elbow injuries in the young athlete. UpToDate, accessed 4/11/12.

Renfrew DL. Single joint pain. Chapter 14 in Symptom Based Radiology, Symptom Based Radiology Publishing, Sturgeon Bay, WI, 2010, available for no charge at www.symptombasedradiology.com.

Slabaugh M. Radial head and neck fractures in adults. UpToDate, accessed 4/11/12.

Weissman BN. Diagnostic imaging of joint pain. UpToDate, accessed 11/16/09.