

CLINICAL PRESENTATION AND RADIOLOGY QUIZ QUESTION

A 49 year old otherwise healthy man comes in after experiencing a ten minute episode of neurologic symptoms. He was showering and heard a loud buzzing sound which gradually subsided. Shortly thereafter, he had difficulty in putting on his socks, with clumsiness in both hands. He also developed an unsteadiness on his feet, but denied dizziness. All symptoms resolved completely within ten minutes, however. Which of the following imaging studies is most appropriate for this patient?

- (a) plain films of the skull
- (b) CT of the head performed without contrast material
- (c) MR of the brain performed without and with contrast material, along with an MR angiogram of the arch and carotid arteries and circle of Willis
- (d) no imaging study is necessary in this situation

RADIOLOGY QUIZ QUESTION, ANSWER, AND EXPLANATION

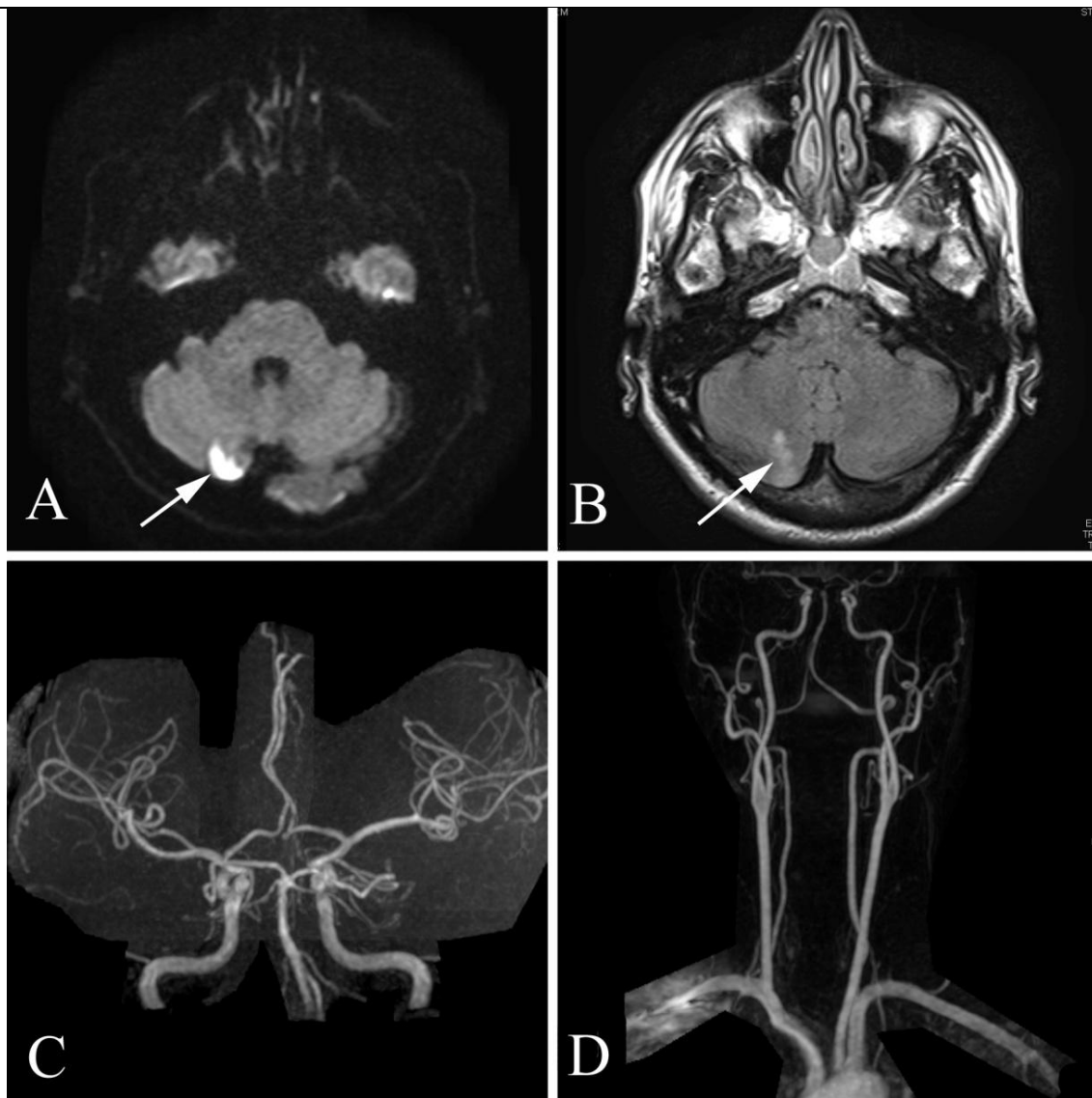
A 49 year old otherwise healthy man comes in after experiencing a ten minute episode of neurologic symptoms. He was showering and heard a loud buzzing sound which gradually subsided. Shortly thereafter, he had difficulty in putting on his socks, with clumsiness in both hands. He also developed an unsteadiness on his feet, but denied dizziness. All symptoms resolved completely within ten minutes, however. Which of the following imaging studies is most appropriate for this patient?

- (a) plain films of the skull
- (b) CT of the head performed without contrast material
- (c) MR of the brain performed without and with contrast material, along with an MR angiogram of the arch and carotid arteries and circle of Willis
- (d) no imaging study is necessary in this situation

Answer: (c), MR of the brain performed without and with contrast material, along with an MR angiogram of the arch and carotid arteries and circle of Willis. The patient has had a definite neural event of some variety, and the issue is whether this represents a transient ischemic attack or stroke. Prior to the widespread availability of imaging, such events were often assumed to be TIAs and their significance was often downplayed, but imaging in such cases will often reveal (as in this case) that a stroke has occurred, even though the patient's symptoms have resolved completely. The brain MR is performed to evaluate whether the patient has had an acute stroke, and the vascular imaging is performed to see if there is a significant, causative abnormality of the stroke (for example, severe stenosis, dissection, or aneurysm).

Plain films of the skull would add nothing to the workup, and (a) is incorrect. CT performed without contrast material is usually helpful in cases where a large acute intracranial hemorrhage is suspected. Given the complete resolution of symptoms there is little reason to suspect that this patient has a significant intracranial hemorrhage, and (b) is incorrect. Imaging is certainly necessary to determine whether the patient has had a stroke, or some other cause of his significant neurologic symptoms, and (d) is incorrect.

IMAGING STUDY AND QUESTIONS

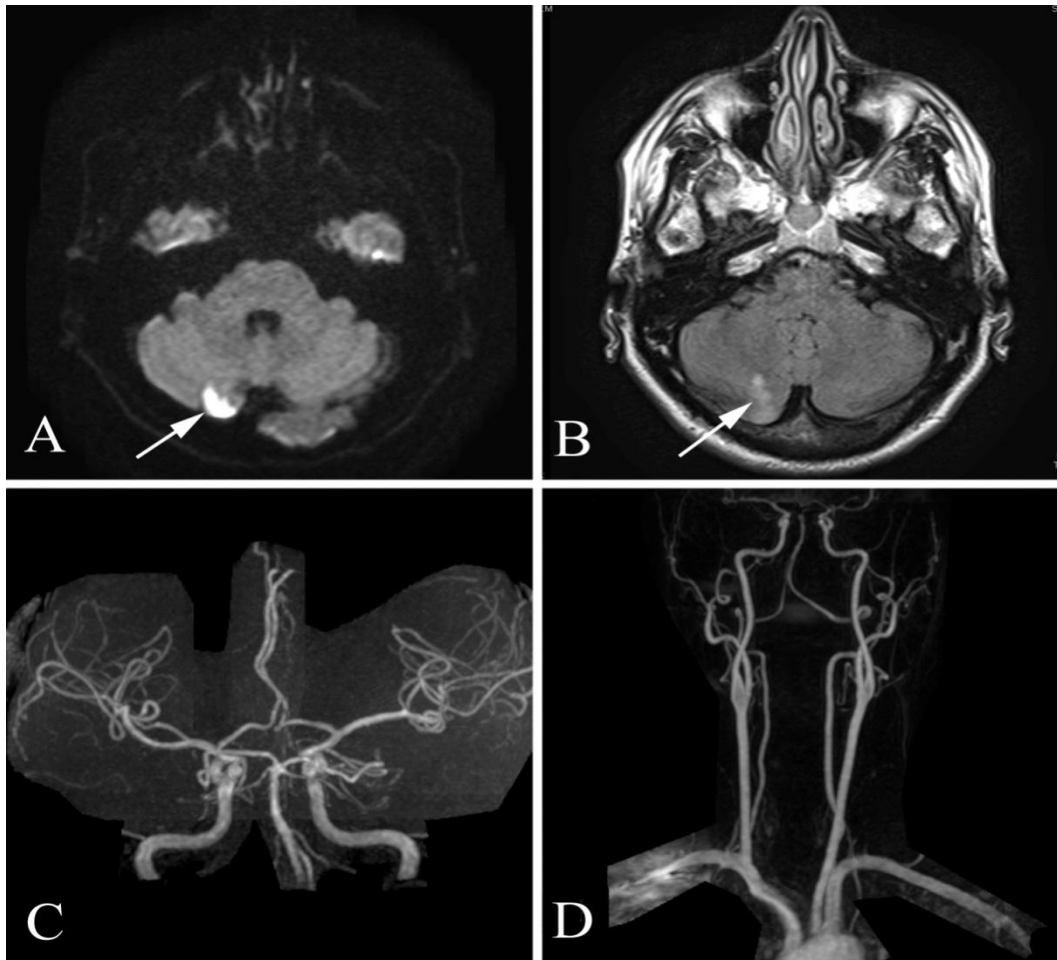


Imaging questions:

- 1) What type of study is shown in figure A? In figure B?
- 2) What is the abnormality indicated by the arrow in figure A? In figure B?
- 3) What is the study shown in figure C?
- 4) What is the study shown in figure D?
- 5) What is the most likely diagnosis?
- 6) What is the next step in management?

IMAGING STUDY QUESTIONS AND ANSWERS

For additional quiz cases and information, please visit www.symptombasedradiology.com



Imaging questions:

- 1) What type of study is shown in figure A? A diffusion weighted magnetic resonance (MR) image. In figure B? A fluid attenuation inversion recovery (FLAIR) image.
- 2) What is the abnormality indicated by the arrow in figure A? Restricted diffusion. In figure B? FLAIR hyperintensity usually caused by T2 prolongation.
- 3) What is the study shown in figure C? A (normal) circle of Willis magnetic resonance angiogram (MRA).
- 4) What is the study shown in figure D? A (normal) arch and carotid magnetic resonance angiogram (MRA).
- 5) What is the most likely diagnosis? A right cerebellar infarction.
- 6) What is the next step in management? Referral to neurology for evaluation of cause of stroke, with further testing including transesophageal echocardiography (TEE).

PATIENT DISPOSITION, DIAGNOSIS, AND FOLLOW-UP

The patient's brain MR showed evidence of an acute infarction (in the right cerebellar hemisphere), despite the complete remission of his symptoms. Other areas of the brain (included on the MR study but not shown here) showed no additional abnormalities, and the patient's arch and carotid MRA and circle of Willis MRA (which included source images and several additional reconstructions in addition to those illustrated here) were both normal.

The patient underwent transesophageal echocardiography, which demonstrated a patent foramen ovale, and his stroke was almost certainly the result of venous side blood-borne clot passing through the foramen and then progressing via left atrium, left ventricle, aorta, and eventually reaching the cerebellar artery branch that served the area of brain showing abnormal signal on the diffusion weighted and FLAIR imaging sequences. Small blood-borne clots typically reach the pulmonary arterial tree, and, unless large enough to produce pulmonary infarction, are typically lysed by the body's fibrinolytic system.

The patient subsequently had his patent foramen ovale repaired, with no further strokes. Timely diagnosis and management on this unusual stroke likely prevented further, more serious strokes, which may have resulted in permanent disability or death.

SUMMARY

Presenting symptom: Neurologic symptoms generally need to be placed in one of several categories to plan imaging. In this case, the patient had a transient episode (10 minutes) of marked neurologic abnormality that had completely resolved by the time he sought medical attention. The rapid, transient nature of the symptoms suggests a transient ischemic event or, possibly, a migraine aura, although the patient had no history of migraine headache.

Imaging work-up: Transient neurologic events which may represent strokes are usually aggressively worked up, because a transient ischemic attack (TIA) may be the harbinger of a serious debilitating or life-threatening stroke. Prior to the era of modern imaging, or if the patient had not undergone imaging, his event may have been classified as a TIA, but the imaging study clearly showed a stroke. While CT is often used in the acute scenario for stroke (mainly to exclude intracranial hemorrhage), MR is more sensitive to stroke. MRA of the arch and carotids and circle of Willis may be performed at the same time (as was done in this case) to evaluate for vascular causes of ischemia.

Establishing the diagnosis: The clinical symptoms and imaging findings in this case establish the diagnosis of stroke; the cause was later found by transesophageal echocardiography. In cases where the imaging findings suggest possible stroke but other diagnoses are also under consideration (tumor, multiple sclerosis, vasculopathy), repeat imaging on a short-term basis (days-weeks) may be helpful since stroke typically shows rapid evolution. In other circumstances, correlation with additional laboratory results (including CSF analysis) or biopsy may prove necessary.

Take-home message: Transient neurologic symptoms, especially if felt to represent an ischemic event, should be worked up aggressively. The symptoms may indicate a stroke, or represent the harbinger of a subsequent stroke that could be potentially debilitating or life-threatening.

FURTHER READING

Caplan LR. Overview of the evaluation of stroke. UpToDate, accessed 10/10/09.

Kistler JP, Furie KL, A H. Definition of transient ischemic attack. UpToDate, accessed 10/26/09.

Kistler JP, Furie KL, A H. Initial evaluation and management of transient ischemic attack and minor stroke. UpToDate, accessed 10/10/09.

Renfrew, DL. Stroke, Seizure, Multiple Sclerosis, and Dementia. Chapter 4 of *Symptom Based Radiology*, Symptom Based Radiology Publishing, Sturgeon Bay, WI, 2010, available for no charge at www.symptombasedradiology.com.