

“First Step” Imaging of Gastrointestinal Symptoms

Donald L. Renfrew, MD

This chapter covers four main points designed to help you order the correct first test when evaluating patients with gastrointestinal (GI) complaints:

1. There are a limited number of “first step” studies for gastrointestinal symptoms: ultrasound (US), computed tomography (CT), and videofluoroscopy.
2. Ultrasound is the imaging study of choice for evaluating right upper quadrant pain and suspected acute pancreatitis. Ultrasound is the best way to figure out if someone has a diseased gallbladder and/or a dilated biliary tree. In pancreatitis, the study is done not so much to see the pancreas itself (although this may be useful) as it is to exclude a reversible cause of obstruction of the pancreatic duct (mainly, gallstones).
3. CT is the imaging study of choice for evaluation of “Abdominal Pain Plus”. Of course, not all patients with abdominal pain need CT imaging, but there are

many instances when they do. This chapter reviews the specific clinical scenarios (and the associated disease processes) when CT is in order.

4. Videofluoroscopy (a “swallowing study”) is often the best first step in evaluation of oropharyngeal dysphagia, whereas endoscopy has supplanted the barium swallow for evaluation of esophageal dysphagia.

THERE ARE A LIMITED NUMBER OF “FIRST STEP” STUDIES FOR EVALUATION OF GASTROINTESTINAL SYMPTOMS

While there are multiple ways to image patients with GI complaints, “first step” studies are few in number, namely, ultrasound, CT, and videofluoroscopy. This section reviews the mechanics of ultrasound, CT, and swallowing studies from the technological point of view, while later sections look at each modality from the patient’s and ordering clinician’s point of view.

Ultrasound

Ultrasound is widely available, does not use ionizing radiation, and is typically considerably lower in cost than CT and MR. These factors have led, particularly in Europe (where there is much more concern about radiation exposure than in the United States), to a nearly universal use of these machines in physician's offices and emergency rooms.

It is easy to forget that ultrasound, like all imaging, is subject to continual improvements of technology. Machines are getting smaller and cheaper, although the bigger machines are still better at providing the best images. The software and hardware are undergoing continual refinements including such features as "harmonic imaging" and higher frequency transducers that allow prettier (and more accurate) pictures. A new type of transducer now allows routine acquisition of volumes of data with "isotropic voxels", enabling routine three-dimensional reformatted images in ultrasound that are widespread in CT. When machines equipped with this technology become widely available, this will greatly reduce the "operator dependence" that has been one of the main drawbacks with ultrasound. Instead of technologists laboring to find the ideal imaging plane and machine settings to visualize a particular part of, for example, fetal anatomy, the technologists will merely have to run the transducer over the patient once or twice, and the rest will be done with imaging processing at a workstation. The time to perform ultrasound studies will go from thirty to sixty minutes to five minutes, and the wait time to get an exam time should approach zero, just as it has for CT with the advent of multi-slice scanners.

When patients come to most radiology departments for ultrasound done for GI symptoms now, however, the technologists still do things the old fashioned way, which is to say, they scan the patient looking for specific items of anatomy. For a right upper quadrant US, the technologist will obtain images of the liver from a number of directions, and try to get the liver in the same scan as the kidney on at least a few pictures, because this allows an evaluation of the relative echogenicity of the liver and kidney. The denser (whiter) the liver is,

the more likely it is to be a fatty liver. The tech will look for masses in the liver and assess the portal vein and hepatic vein, checking for patency and direction of flow in these vessels. Of course, one of the main areas of attention will be the gallbladder. For this organ, the lumen should be free of echoes and the wall thickness should be uniform and measure less than 2 mm, and the margins should be against either the liver or the bowel without intervening fluid. The technologist should note whether the patient is tender when the probe is placed directly over the gallbladder for scanning (which typically requires at least some light pressure), and record this as a "sonographic Murphy's sign". The intrahepatic ducts will be included as part of the evaluation of the liver. The common duct is typically measured where it is next to the portal vein. This may be either above the junction of the common hepatic duct (formed by the confluence of the right and left hepatic ducts) and cystic duct, or below this junction. Therefore, it is often not possible to say whether the measurement pertains to the common hepatic duct or the common bile duct, so the correct wording is probably "common duct". Regardless, the measurement should be 7 mm or less in patients less than 60 years of age, and 10 mm or less in older patients¹, at least in patients who still have their gallbladder. The pancreas is often not well seen on abdominal ultrasound, particularly the tail. The body may be relatively well evaluated depending on bowel contents, and longer periods of fasting are generally associated with better visualization of the pancreas. Even seeing a portion of the body and head allows evaluation of the pancreatic duct, which is important to see in patients with possible pancreatitis, to make sure it is not dilated. The right kidney is routinely included in this evaluation, because right kidney hydronephrosis, a stone, or tumor could cause right upper quadrant pain.

Radiology departments usually offer both "right upper quadrant" ultrasound studies for evaluation of the liver, gallbladder, biliary tree, pancreas, and right kidney, and a "complete abdomen ultrasound" which evaluates the same structures plus the left kidney, aorta, and inferior vena cava. The "complete" study is typically done to survey the entire abdomen, and in this regard the study comes

in a poor second to the abdominal CT for most disease processes, even a CT done without IV contrast (see below). However, it can be done as a portable exam. Even so, “complete abdominal ultrasound” is generally not a “first step” study for gastrointestinal complaints.

Computed Tomography

There has been a revolution over the past decade or so in CT scanning as multi-slice scanners changed the industry. Isotropic voxels (imaging volumes with the same resolution in all three planes) allow multiplanar reformatting and other methods of data interrogation that leads to improved diagnosis. In addition, the time required to perform a CT scan dropped from an hour or more to a few seconds, and most of the time “scanning” a patient is now spent either waiting for orally administered contrast material to travel through the gastrointestinal system, intravenously administered contrast material to travel through the circulatory system, or to get the patient on and off the table.

Note that, for the most part, a radiologist will be responsible for setting the protocol for performance of the CT study, taking into account the clinician’s request and the patient’s condition. It is certainly possible to perform a CT study with neither IV nor oral contrast material, a so-called “CT-KUB”. As noted in Chapter 1, the main use of the CT-KUB is for suspected renal stone disease. Typically, it is best to perform more than the CT-KUB for evaluation of GI issues. Obviously, the bowel is much better seen with contrast material in the lumen, and it is only possible to fully assess many solid organ tumors, vascular abnormalities, and bowel wall lesions with IV contrast. Therefore, most studies will be performed with some combination of oral and IV contrast.

While the radiologist sets the protocol for CT studies based on patient symptoms and laboratory data, the necessity to improve quality by maintaining a uniform technique results in many studies being done with what may be called a “routine” technique for abdomen and pelvis examination involving oral and IV contrast. Positive oral contrast may be provided by dilute oral barium (more often used) and dilute oral water-soluble non-ionic contrast (preferred in those cases where there

is any question of contrast extravasation from perforation). IV contrast has, of course, evolved through time. Modern nonionic contrast is designed to be less nephrotoxic than the ionic contrast material of yesteryear, and some recent papers have challenged the entire concept of whether modern nonionic water soluble contrast materials are nephrotoxic at all². Nonetheless, most departments routinely assess renal function and use a combination of features including serum creatinine, glomerular filtration rate, and patient circumstances to determine whether to give intravenous contrast or not. In some cases, either hydration (for borderline renal insufficiency issues) or premedication with steroids (in cases of patient allergies) may be used. See Chapter 16 for a longer discussion of IV contrast material.

With regard to enteric contrast, in some cases, particularly in patients with known inflammatory bowel disease undergoing work-up for small bowel inflammatory changes, the routine dense, positive contrast within the bowel impedes visualization of inflammatory changes in the bowel wall which may be seen following IV injection of contrast material. Manufacturers have developed a low density contrast material for studying these patients. Woo et al³ found that whole milk is just as good at bowel distension and visualization, cheaper, and preferred by patients.

In addition to, or instead of, enteric *oral* contrast material, enteric *rectal* contrast material allows excellent distention and study of the large bowel, which is typically poorly distended with only oral contrast. Rectal contrast may be particularly useful in patients suspected of diverticulitis or appendicitis.

With regard to the timing of scans following intravenous injection of contrast material, the ability to acquire a scan in a few seconds with multi-slice CT scanners permits evaluation at any of several phases of vascular opacification. Routine studies are typically performed as “two phase” examinations. The first phase is the so-called “portal venous phase” (which in most normal patients occurs 60 – 90 seconds following beginning of the IV injection) which shows the portal venous system, but also the arterial tree. A later, delayed, scan allows evaluation of the urinary tract collecting system including the renal pelves, ureters, and bladder, as

well as the dynamics of any contrast enhancing lesions such as hemangiomas of the liver.

The radiologist may alter this sequence, typically in one of a few specific ways:

- 1) Obtaining a precontrast study to evaluate renal stones which may be obscured following contrast material, solid tumors such as adrenal adenomas where the pre-contrast images may allow density measurements to allow histologic specificity, and aortic wall density to check for hematoma formation. Of course, it may not be clear that you need a non-contrast study until after the fact, and therefore the patient may need to return to the department at a later time. Performing all studies without IV contrast as a routine would be possible but low yield, and, it is thought, does not justify the additional expense and radiation exposure.
- 2) Obtaining an arterial phase study, to get an even better look at the arterial tree than is allowed by the portal venous phase and to check for early contrast enhancement of some tumors.
- 3) Obtaining additional, more delayed studies, usually to confirm liver hemangiomas or to evaluate the urinary tract when there is pathologically delayed filling.

Barium Studies and Plain Films

There was a time twenty to thirty years ago when barium studies formed a large proportion of the work done in a radiology department. At that time, barium studies using oral contrast were routinely employed to evaluate mucosal disease, namely esophagitis, gastritis, gastric ulcers, duodenitis, duodenal ulcers, malignancies of the esophagus, stomach, and proximal small bowel, whereas barium administered rectally was used to evaluate polyps, villous adenomas, and malignancies of the large bowel. Water soluble upper GI studies were used in the post-operative situation, and water-soluble enemas for both post-operative situations and for evaluation of suspected diverticulitis. Almost all of these indications now result in the ordering of different studies, usually either optical endoscopy or cross-sectional imaging. There is

basically a single exception where a barium study is still considered a "first step" examination for evaluation of gastrointestinal symptoms and that is videofluoroscopy for oropharyngeal dysphagia.

Dysphagia, or difficulty swallowing, may be divided into oropharyngeal dysphasia, accompanied by difficulty initiating a swallow, choking, and an abnormal feeling in the throat or cervical region, and esophageal dysphagia, or difficulty swallowing with the abnormal sensation in the lower chest and typically occurring several seconds following swallowing⁴. Videofluoroscopy studies, done for oropharyngeal dysphagia, are done in conjunction with a speech pathologist. These studies are typically recorded on videotape. The study allows evaluation of swallowing function using a variety of substances, typically starting with thin (water consistency) barium, and proceeding to nectar thickness, honey thickness, applesauce, thin liquid barium with fruit cocktail, barium smeared over pieces of meat, and barium on a graham cracker. Usually, the test is finished off by observing the passage of a 13 mm barium tablet through the esophagus. The idea is to test the function of the oropharynx, hypopharynx, epiglottis, and proximal esophagus in the usually smooth, even flow of material from above to below, avoiding the larynx and trachea. With the swallowing study, the main report on the examination, as well as the recommendations for treatment, will typically come from the speech pathologist performing the procedure, with a radiology report usually providing a relatively limited summary of the main findings. Endoscopy has largely supplanted the barium swallow in the evaluation of esophageal dysphagia.

Plain films of the abdomen have largely been replaced by ultrasound (for right upper quadrant pain suggesting biliary disease) and CT (for other indications). The role of plain films is limited because the plain films are rarely definitive: typically, they add little and another imaging examination (most frequently CT) is done anyway⁵.

ULTRASOUND IS THE IMAGING STUDY OF CHOICE FOR EVALUATING RIGHT UPPER QUADRANT PAIN AND SUSPECTED PANCREATITIS

Ultrasound is the examination of choice for suspected biliary disease⁵. The first finding to look for in the case of someone with right upper quadrant pain is a gallstone (or gallstones) in the gallbladder (Figure 1). Such stones are likely the cause of the patient’s abdominal pain, particularly if accompanied by: a classic history; a positive physical examination finding of tenderness over the gallbladder; a positive “sonographic Murphy’s sign”; or additional imaging findings such as the stone being lodged in the gallbladder neck or accompanied by gallbladder wall thickening or pericholecystic fluid. However, it is good to keep in mind that many people harbor asymptomatic gallstones, and right upper quadrant pain and gallstones may co-exist even when the stones are not the cause of the pain. When the pain is atypical or not accompanied by other imaging features, be suspicious of alternative diagnoses such as gastritis, duodenitis, or ulcer disease. On the other hand, elderly patients may have cholecystitis *without* classic right upper quadrant pain, epigastric pain, or enzyme abnormalities: they may simply have nausea and vomiting⁶.

In addition to gallstones, a finding which may accompany gallstone disease is a dilated biliary duct. The upper limit of a normal duct is typically taken to be about 7 mm, although slightly larger measurements may be encountered in the elderly. A dilated biliary duct in a patient with cholelithiasis may occur because of a stone lodged in the duct downstream from the dilatation (choledocholithiasis) or residual dilatation from prior passage of stones. Since the common duct is tricky to examine through its length by ultrasound, additional tests including nuclear medicine studies, magnetic resonance cholangiopancreatography (MRCP), or endoscopic retrograde cholangiopancreatography (ERCP) may be necessary to evaluate patients when there is a strong suspicion of choledocholithiasis (See page 106). The

determination of whether to perform these tests is usually made by a gastroenterologist or GI surgeon.

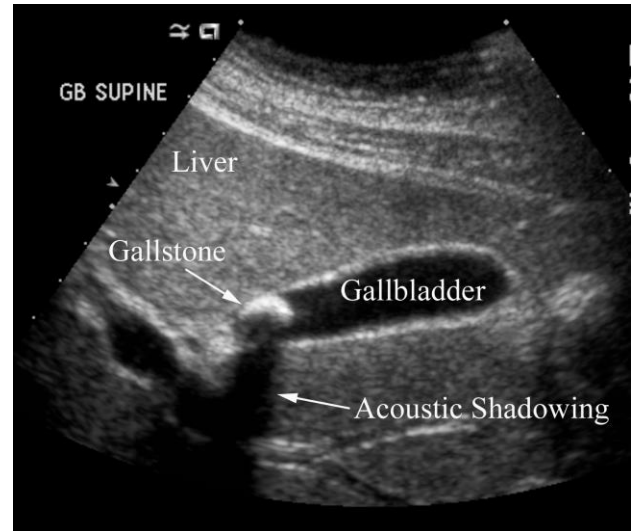

Figure 1. Gallstone disease in a 31 year old woman with right upper quadrant pain. Ultrasound demonstrates a hyperechoic, shadow casting structure within the gallbladder diagnostic of a gallstone.

Other additional features of gallstone disease include a thick walled gallbladder and pericholecystic fluid, which suggest inflammation from acute cholecystitis. Again, clinical features are the key: if accompanied by recurrent right upper quadrant pain and gallbladder tenderness, or a sonographic Murphy’s sign, the diagnosis is obvious. The issue is more complicated in patients with congestive heart failure, because accompanying hepatic congestion may cause right upper quadrant pain and ascites, and ascites may collect around the gallbladder as pericholecystic fluid, mimicking the inflammatory fluid of cholecystitis.

Regarding suspected pancreatitis, it is important to exclude gallstone pancreatitis, caused by choledocholithiasis downstream from the insertion of the pancreatic duct into the common bile duct, as a reversible cause of acute pancreatitis, and ultrasound is the study of choice to accomplish this goal. CT will typically better demonstrate the inflammatory changes around the pancreas than ultrasound. In severely ill patients, CT allows evaluation of significant peripancreatic fluid collections which may require drainage, and also allows evaluation of pancreas perfusion (which

provides important prognostic information about the likely course of pancreatitis for a given patient). It may be necessary to perform both US and CT in a given individual if the diagnosis is in doubt. If the ultrasound documents a normal appearance of the gallbladder and pancreas and the patient has typical clinical and laboratory features of mild pancreatitis, particularly if there is an identifiable offending agent such as alcohol involved, it is probably reasonable to treat the patient as having pancreatitis without CT or other additional imaging.

CT IS THE IMAGING STUDY OF CHOICE FOR EVALUATION OF “ABDOMINAL PAIN PLUS”

The simple way of thinking about pain is that it arises from stimulation of nerve fibers. The autonomic nerve fibers of the viscera react to distension, whereas both these visceral nerve fibers and the somatic nerve fibers of the peritoneum react to inflammation. Abdominal nerve fibers tend not to react to cutting or tearing. Therefore, those things that cause distension and inflammation lead to pain. In general terms, endoscopy tends to work best for evaluation of those diseases which cause inflammation of the mucosal lining, whereas imaging offers a better evaluation for those processes causing obstruction, particularly if the obstruction has resulted in distension of the obstructed structure. Examples of the obstruction-distension-pain process include: gallstones in the gallbladder neck, cystic duct, or biliary tree; appendicoliths or lymphoid tissue obstructing the appendix, and fecaliths obstructing diverticulae. In many cases, the obstruction also produces inflammation secondary to the dilated structure’s lining stretching to the point where it leaks: typically, the contents of these structures irritate the adjacent tissue or (in the case of some bowel contents) infects them, leading to inflammatory pain. From the clinical standpoint, it may be quite difficult to tell prior to the work-up which of the two categories (mucosal inflammation or obstructed structure) the patients fits into, and whether endoscopy or imaging may offer the best chance of providing a diagnosis. Additional features of the pain may help

in the process of test selection. In the scenario of abdominal pain with features suggesting biliary colic or pancreatitis, as noted above, ultrasound is the first study of choice. In most other instances of “abdominal pain plus another feature” where imaging needs to be performed, CT is the first imaging study of choice. This section reviews those features.

Abdominal pain and inflammation

Patients may present with abdominal pain and features of inflammation, such as fever or an elevated white blood cell count, ESR, or C-reactive protein. Statistically, you are looking for one of a few disease processes: appendicitis, diverticulitis, and appendagitis epiploicae.

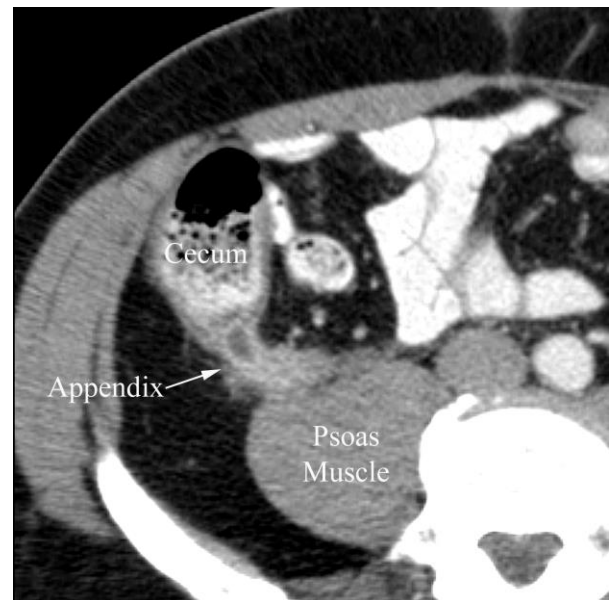


Figure 2. Appendicitis in a 52 year old man with right lower quadrant pain. CT study through the right lower quadrant performed with oral and IV contrast shows a swollen appendix with marked contrast-enhancement of the appendix wall along with periappendiceal fat stranding.

Appendicitis

Appendicitis may follow obstruction of the appendix, typically by an appendicolith but also by lymphoid tissue along the base of the appendix⁷. This obstruction results in distension of the appendix and subsequent leakage of material from the appendix, with inflammatory change of the periappendiceal fat and/or fluid in the peritoneal

cavity (Figure 2). The process may eventually result in rupture of the appendix with extraluminal fluid and/or air in the right lower quadrant. This process may take several hours, and patients typically initially have generalized pain which, through time, localizes to McBurney’s point (halfway between the umbilicus and anterior superior iliac spine). These patients typically lose all appetite and often have nausea and vomiting. When the patient has a classic clinical presentation accompanied by an elevated WBC, emergent surgical consultation should follow, which will likely be followed by emergent appendectomy.

Not all presentations of appendicitis are classic: frequently, patients will not have an elevated white count, or will have hematuria or pyuria, complicating clinical diagnosis. When you suspect appendicitis but the diagnosis remains uncertain following clinical and laboratory examination, CT is usually the study of choice. Ideally, this CT will be performed with both oral and intravenous contrast material. The use of oral contrast in these cases may present a problem. The benefit of oral contrast is that it opacifies the bowel and makes it easier to diagnose bowel abnormalities, which are among the chief causes of abdominal pain. Detriments include that the nauseated patient may not tolerate oral contrast, that CT scanning should optimally be performed at a minimum two hours *after* beginning to ingest oral contrast to allow time for the contrast to reach the large bowel, and that if the patient goes to surgery immediately following the CT exam, the enteric contents increase the risk of GE reflux, vomiting, and aspiration pneumonia. Accordingly, it may be reasonable to perform a so-called “CT-KUB” or unenhanced CT of the abdomen and pelvis, as is done for suspected renal stone disease (see pages 6-7), since renal stones are in the differential diagnosis for many of these patients anyway. Such an unenhanced exam will often demonstrate appendicitis well, particularly in patients who sport a few extra pounds (where intraperitoneal fat surrounds bowel loops and the appendix). Of course, the CT-KUB may be equivocal or nondiagnostic, in which case the best next step is usually to give the patient oral contrast and scan the patient in two hours with both oral and IV contrast.

Ultrasound (US) examination of the appendix has long been advocated as a useful study in evaluation of patients with suspected appendicitis and remains popular in some radiology departments as the *initial* study of choice, particularly for pregnant women and pediatric patients. Ultrasound findings include demonstration of appendiceal swelling or an appendicolith. US is highly “operator dependent,” however, and unless the ultrasonographer is skilled and experienced with ultrasound for appendicitis, the exam is prone to false-negatives. Since CT usually follows a negative US in a patient where appendicitis needs to be excluded, the addition of ultrasound to the work-up may simply add expense and delay diagnosis. A more recently developed alternative to performing CT in pregnant women suspected of appendicitis is MR, which may demonstrate appendiceal swelling and periappendiceal inflammation⁸. MR almost certainly has fewer adverse consequences for the fetus than CT, but because of the relative novelty of the use of MR for appendicitis, it makes sense to consult the radiologist prior to ordering the exam.

Diverticulitis

Similar to gallstone disease and renal colic, diverticulitis likely follows obstruction. In diverticulitis, the obstruction occurs at the lumen where the diverticulae communicate with the bowel. The diverticulum then swells and leaks (microperforation), causing pericolic inflammation and associated fat stranding, or frankly ruptures (macroperforation), leading to greater degrees of inflammation or free air in the peritoneal cavity⁹ (Figure 3). Bowel wall thickening may be secondary to inflammation, or it may be secondary to circle muscle hypertrophy which accompanies chronic diverticulosis. Since most diverticulae are in the sigmoid colon, most patients have low pelvic pain, but diverticulae, and diverticulitis, may occur anywhere along the course of the large bowel. While patients with diverticulitis may have changes in bowel habits, they often do not, and simply present with lower abdomen or pelvic pain. While diverticulitis preferentially affects the elderly, more people are being diagnosed with diverticulitis at a younger age. This is probably secondary to dietary

changes leading to diverticulosis earlier in life, and the widespread use of CT to evaluate abdominal pain which would have, in earlier eras, been treated empirically without a specific diagnosis.

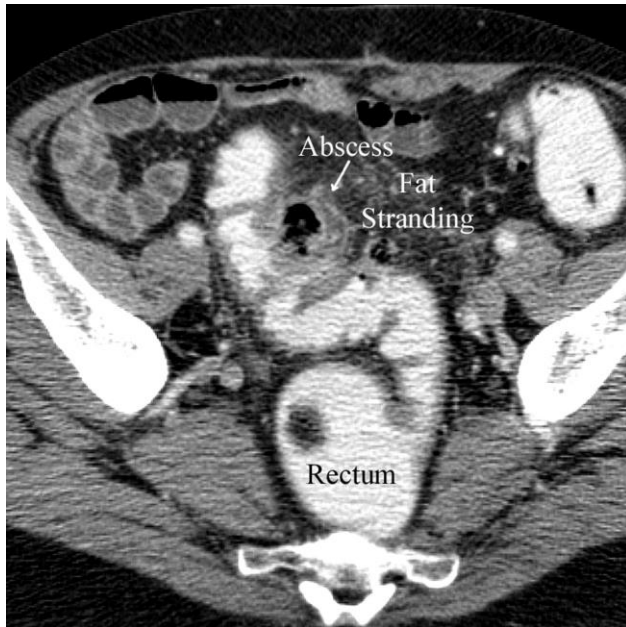


Figure 3. Diverticulitis in a 62 year old man with lower abdomen and pelvic pain. Axial CT performed with rectal contrast shows sigmoid colon wall thickening, pericolic fat stranding, and a pericolic abscess.

Patients with suspected diverticulitis typically undergo CT performed with oral and IV contrast. Oral contrast often does a poor job of filling the colon regardless of the time of the scan, however, and some radiology departments advocate routine use of rectal contrast in cases of suspected diverticulitis, a practice which is unpopular with both the patients and the technologists.

Inflammatory change in pericolic fat adjacent to a diverticulum in the setting of abdominal pain establishes the diagnosis of diverticulitis, and the patient will need appropriate treatment with antibiotics. These patients must subsequently undergo colonoscopy (typically done a few weeks after the acute bout of inflammation has regressed), not to document the diverticulae or any residual inflammation, but to exclude causative or coincident neoplasm in the colon. Large perforations of the sort associated with extraluminal air (or infection with gas producing organisms) and abscesses both merit emergent surgical consultation. The surgeon may

opt for emergent surgery or elect to admit the patient for IV antibiotics and bowel rest prior to intervention. Percutaneous abscess drainage may be performed prior to surgery.

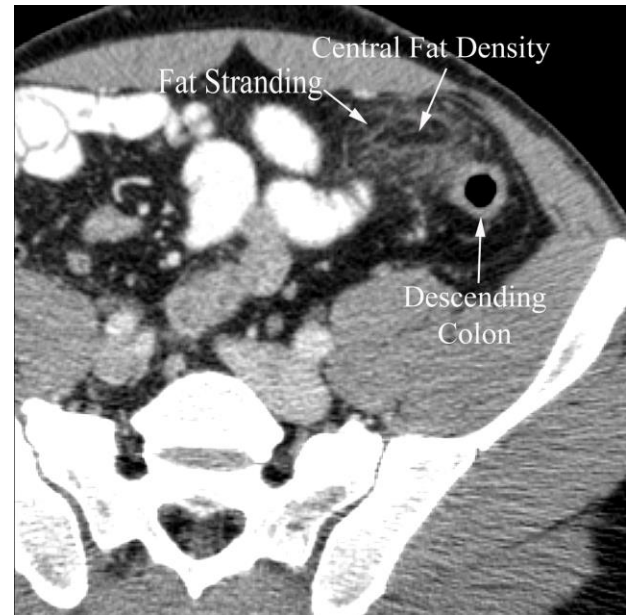


Figure 4. Appendagitis epiploicae in a 35 year old man with right lower quadrant pain. Axial CT performed with oral and intravenous contrast demonstrates soft tissue stranding in the pericolic fat along the descending colon with a central area of fatty density.

Appendagitis Epiploicae

Appendagitis epiploicae is another painful inflammatory condition of the bowel which may mimic diverticulitis¹⁰. This self-limited entity was likely under-diagnosed in the past because it usually resolves without the necessity of surgery (and, therefore, a lack of a correlating pathologic diagnosis). With the widespread use of CT in the evaluation of patients with acute abdominal pain and features of inflammation, appendagitis epiploicae is being diagnosed more frequently. Appendagitis epiploicae likely follows torsion of the epiploic appendages (fatty outpouchings along the bowel margin), which results in infarction of the fat and a highly characteristic CT picture (Figure 4). These patients nearly always respond to conservative measures (pain relievers), with prompt resolution of symptoms.

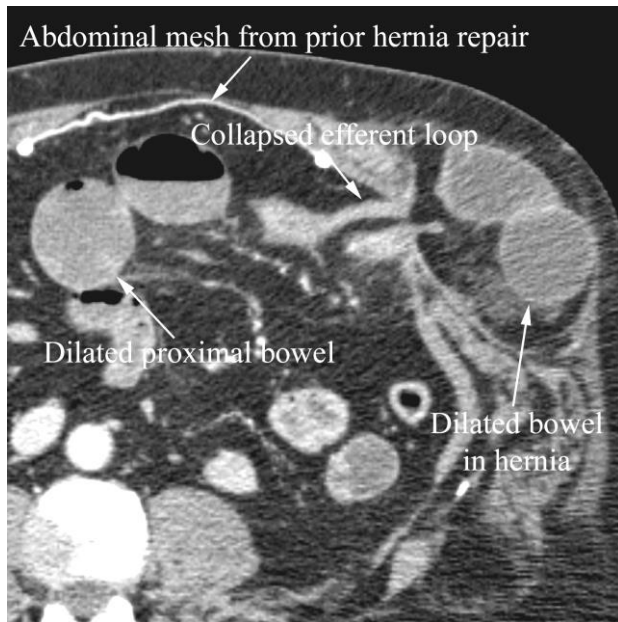


Figure 5. Small bowel obstruction from hernia in a 52 year old man with abdominal distension and a history of prior surgery. Axial CT shows dilated bowel loops proximal to and within the hernia, collapsed distal loops, and a transition point in the loop leading out of the hernia. Note the mesh in the anterior abdominal wall from prior hernia repair.

Abdominal pain and suspected obstruction

Patients who present with abdominal pain with distension may or may not have nausea and vomiting⁵. Those who have nausea and vomiting, of course, must be suspected of having bowel obstruction. The physical exam should focus on the presence and quality of bowel sounds and hernias. There is ongoing debate regarding the utility of plain films in the evaluation of such patients. Certainly, the plain film may show features of bowel obstruction such as distended small bowel loops, air fluid levels, and a paucity of colonic contents. However, the study may be falsely negative, and typically does not provide the location or cause of the obstruction. CT can often provide both (Figure 5). In cases of severe obstruction with vomiting, the study should be performed with only IV contrast (the patient will simply vomit the oral contrast anyway). The patient may tolerate oral contrast in cases of low grade or intermittent obstruction. Key findings in bowel obstruction include distended small bowel (normal small bowel should measure no more than about 25 mm) and the presence and

location of a *transition point*. The transition point, or location where the small bowel abruptly changes caliber from dilated to collapsed, is the key to the diagnosis¹¹. There may be a hernia, volvulus, or a mass at the transition point, or there may be inflammatory changes suggesting a stricture from inflammatory bowel disease. If there is a transition point and no specific cause is identified, the bowel obstruction is likely secondary to adhesions. If there is no transition point and the entire bowel is distended, ileus or pseudo-obstruction is more likely.

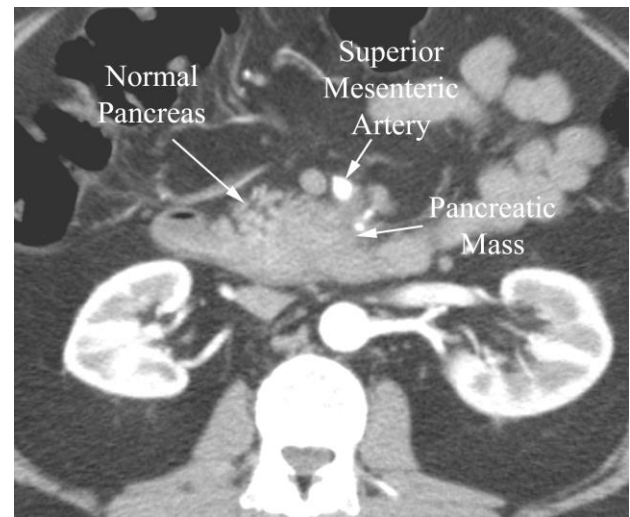


Figure 6. Pancreatic cancer in a 43 year old man with weight loss and abdominal pain. Axial CT performed during the arterial phase demonstrates tumor in the pancreas effacing the normal lobulated (with fat) appearance. The tumor surrounded the superior mesenteric artery more superiorly (not shown).

Abdominal pain and weight loss

Another scenario in which CT should be considered is when patients have abdominal pain and such constitutional symptoms as weight loss (Figure 6). Possible causes include intestinal ischemia (particularly for those with such risk factors as known vascular disease or diabetes) (see page 177) and occult malignancy (particularly of the pancreas).

Abdominal pain and diarrhea

Multiple diseases may cause colitis and result in both abdominal pain and diarrhea, chief among them pseudomembranous colitis¹² (Figure 7) and ischemic colitis¹³. Both may be associated with CT

findings of diffuse colon wall thickening and pericolic fat stranding. Patients with either pseudomembranous colitis or ischemic colitis will likely require hospitalization. CT is the imaging study of choice, but as with other diagnoses associated with abdominal pain and diarrhea, the patient may undergo endoscopy first with no CT scan performed.

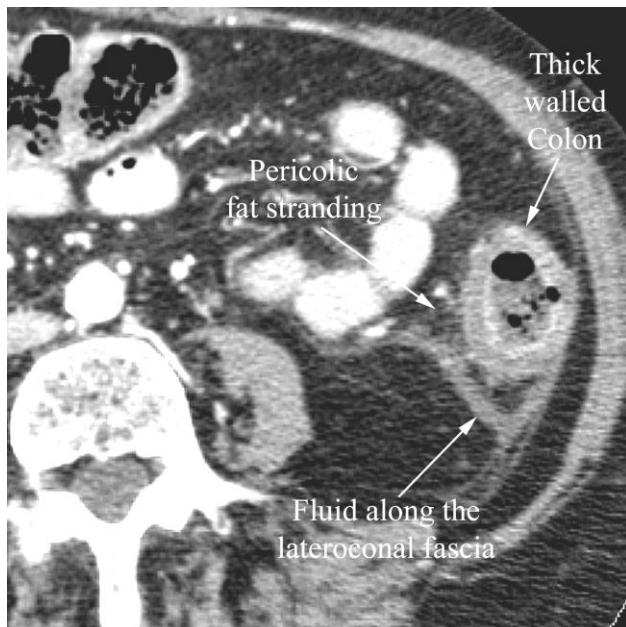


Figure 7. Pseudomembranous colitis in an 88 year old woman with diarrhea following antibiotic treatment. CT demonstrates a thick walled colon and pericolic fat stranding as well as fluid along the lateroconal fascia.

This should not leave you with the impression that all abdominal pain needs to be worked up with CT examination. As noted above, in patients with suspected biliary disease and in those with straightforward acute pancreatitis where no complication such as abscess or pancreatic necrosis is suspected, the first step of the work-up is with ultrasound rather than CT. Also as noted above, abdominal pain of mucosal origin is now largely evaluated with endoscopy, which has replaced barium studies. Cross-sectional imaging is performed as a complementary procedure in patients undergoing endoscopy. For example, in patients with colon cancer diagnosed with endoscopy, CT is typically performed to assess not the colon mucosa or the primary tumor (although the primary tumor is often visible), but to evaluate

lymphadenopathy and possible liver lesions. In addition, many patients have chronic abdominal pain which has been worked up extensively in the past, and reimaging such chronic pain patients is infrequently rewarding (see page 101).

VIDEOFLUOROSCOPY IS OFTEN THE BEST FIRST STEP IN EVALUATION OF OROPHARYNGEAL DYSPHAGIA

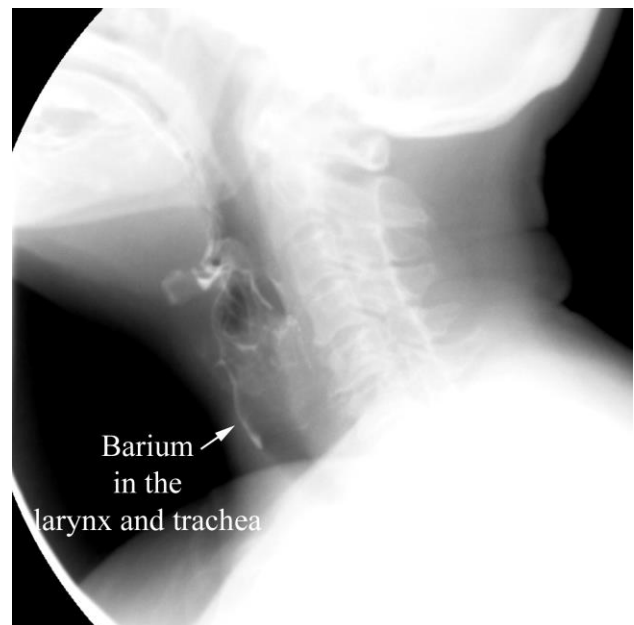

Figure 8. Aspiration in a 75 year old woman with oropharyngeal dysphagia. Lateral image obtained during videofluoroscopy shows aspirated barium in the larynx and trachea.

Videofluoroscopy swallowing studies are designed to test the function of the oropharynx, hypopharynx, epiglottis, and proximal esophagus in the usually smooth, even flow of material from above to below, avoiding the larynx and trachea¹⁴. While videofluoroscopy allows analysis of the swallowing mechanism in great detail, the main reproducible findings are *penetration*, or barium flowing abnormally past the epiglottis and into the supraglottic larynx, and *aspiration*, or barium flowing past the true vocal cords into the trachea¹⁵(Figure 8). These are both associated with a significantly increased risk for pneumonia, and are responsible for the choking episodes characteristic of oropharyngeal dysphagia.

A lesion that may be diagnosed with either videofluoroscopy or with a barium esophagram is a Zenker’s diverticulum (Figure 9). These more frequently lead to oropharyngeal dysphagia than esophageal dysphagia, since they are proximally located in the esophagus and give rise to such symptoms as difficulty shortly after initiating a swallow, gurgling, or a full sensation in the throat. Retention of food within these diverticulae can compress the esophagus, which leads to difficulty after the first or second swallow. The patient then has to wait for the diverticulum to empty, which may result in regurgitation of food, before being able to resume eating.

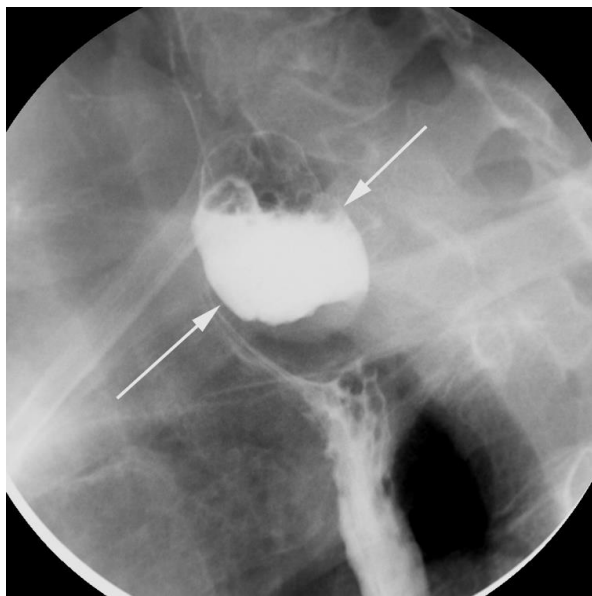


Figure 9. Zenker’s diverticulum in a 75 year old with dysphagia. There is a large Zenker’s diverticulum in the typical location along the posterior, proximal esophagus.

SUMMARY

While there are many different imaging studies which may be performed on patients with gastrointestinal complaints, first step studies include ultrasound for evaluation of biliary colic and pancreatitis, CT for “abdominal pain plus”, and videofluoroscopy for oropharyngeal dysphagia.

REFERENCES

- ¹ Karnam US et al. Ultrasonography of the hepatobiliary tract. UpToDate, accessed 8/3/09.
- ² Newhouse JH et al. Frequency of serum creatinine changes in the absence of iodinated contrast material: implications for studies of contrast nephrotoxicity. *AJR* 2008; 191:376-382
- ³ Woo CW et al. Cost-effectiveness and patient tolerance of low-attenuation oral contrast material: mild versus VoLumen. *AJR* 2007; 190:1307-1313.
- ⁴ Fass R. Approach to patient with dysphagia. UpToDate, accessed 7/7/09.
- ⁵ Penner RM, Majumdar SR. Diagnostic approach to abdominal pain in adults. UpToDate, accessed 7/6/09.
- ⁶ Parker LJ et al. Emergency department evaluation of geriatric patients with acute cholecystitis. *Acad Emerg Med* 1997; 4:51-55
- ⁷ Goldberg JE, Hodin RA. Appendicitis in adults. UpToDate, accessed 7/7/09.
- ⁸ Pedrosa I et al. MR imaging evaluation of acute appendicitis in pregnancy. *Radiology* 2006; 238:891-899
- ⁹ Young-Fadok T, Pemberton JH. Clinical manifestations and diagnosis of colonic diverticular disease. UpToDate, accessed 7/14/09.
- ¹⁰ Gelrud A, Cardenas A, Chopra S. Epiploic appendagitis. UpToDate, accessed 7/7/09
- ¹¹ Silva AC et al. Small bowel obstruction: what to look for. *RadioGraphics* 2009; 29:423-439.
- ¹² LaMont JT. Clinical manifestations and diagnosis of clostridium difficile infection. UpToDate, accessed 7/14/09.
- ¹³ Grubel P and Lamont JT. Colonic ischemia. UpToDate, accessed 7/14/09.
- ¹⁴ Lembo AJ. Diagnosis and treatment of oropharyngeal dysphagia. UpToDate, accessed 7/6/09.
- ¹⁵ Stoeckli SJ et al. Interrater reliability of videofluoroscopic swallow evaluation. *Dysphagia* 2003; 18:53-57.