

CLINICAL PRESENTATION AND RADIOLOGY QUIZ QUESTION

A 49 year old woman presents with a five day history of nausea, dizziness, and headache. She also complains of posterior neck pain. Movement does not make the dizziness worse. She denies focal weakness, numbness, paresthesias, visual changes, speech difficulties, or any other acute neurologic abnormalities. She has a history of hypertension. She does not smoke or drink. Her blood pressure is 237/122, her pulse is 80, her respiratory rate is 16, and her temperature is 97.8. On physical examination, she has no neurologic deficit. Her neck is nontender and she has a full range of motion. The patient underwent an emergency unenhanced head CT which was normal.

Which of the following imaging studies are appropriate to consider in this patient, and why?

- (a) renal ultrasound with evaluation of the renal arteries to evaluate for renal artery stenosis
- (b) myocardial perfusion stress test to evaluate for acute myocardial infarction
- (c) emergency cervical myelogram with CT to evaluate for cervical disc herniation
- (d) CT angiography of the arch and cervical vessels to evaluate for vascular dissection

RADIOLOGY QUIZ QUESTION, ANSWER, AND EXPLANATION

A 49 year old woman presents with a five day history of nausea, dizziness, and headache. She also complains of posterior neck pain. Movement does not make the dizziness worse. She denies focal weakness, numbness, paresthesias, visual changes, speech difficulties, or any other acute neurologic abnormalities. She has a history of hypertension. She does not smoke or drink. Her blood pressure is 237/122, her pulse is 80, her respiratory rate is 16, and her temperature is 97.8. On physical examination, she has no neurologic deficit. Her neck is nontender and she has a full range of motion. The patient underwent an emergency unenhanced head CT which was normal.

Which of the following imaging studies are appropriate to consider in this patient, and why?

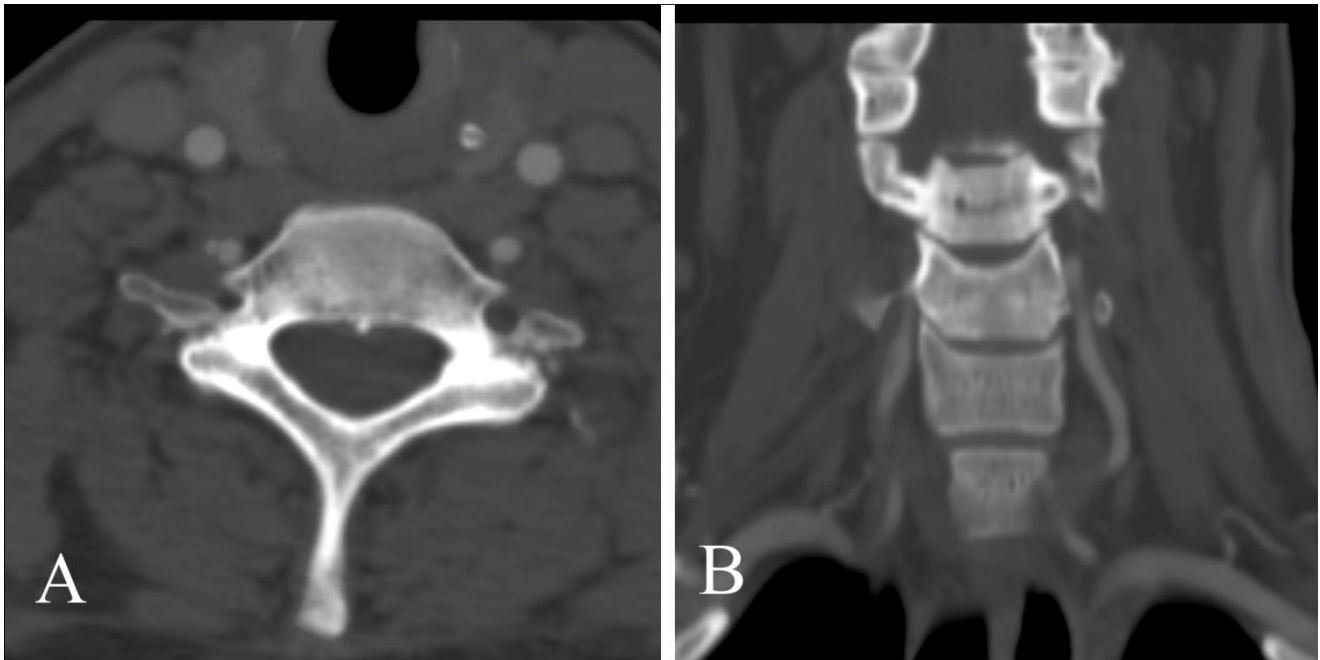
- (a) renal ultrasound with evaluation of the renal arteries to evaluate for renal artery stenosis
- (b) myocardial perfusion stress test to evaluate for acute myocardial infarction
- (c) emergency cervical myelogram with CT to evaluate for cervical disc herniation
- (d) CT angiography of the arch and cervical vessels to evaluate for vascular dissection

Answer: (d), CT angiography of the arch and cervical vessels to evaluate for dissection. The patient has a combination of symptoms which bring to mind multiple diagnoses. Her acute headache and focal neck pain could be explained by an acute herniated disc or meningitis, but both of these processes would likely be accompanied by cervical spine tenderness or a limited range of motion or both. In addition, her nausea and dizziness suggest a possible neurologic event, and markedly elevated blood pressure may accompany cervical artery dissection.

Renal ultrasound with evaluation of the renal arteries to evaluate for renal artery stenosis (a) is incorrect. Renal artery stenosis should be considered in those patients with early onset hypertension or hypertension difficult to control with multiple antihypertensive medications but is not typically a cause of acute neck pain, headache, and dizziness. Furthermore, CT angiography or MR angiography are preferred to ultrasound for evaluation of the renal arteries in cases of suspected renovascular hypertension. See Radiology Quiz of the Week 003 Hypertension 01-15-11. Myocardial perfusion stress test to evaluate for acute myocardial infarction (b) is incorrect. Isolated posterior neck pain (without chest, arm, or jaw pain) with headache and dizziness would be a distinctly unusual presentation of myocardial infarction, and even if myocardial infarction is suspected, a myocardial perfusion stress test would not be appropriate in the setting of an acute event. Emergency cervical myelogram with CT to evaluation for cervical disc herniation (c) is incorrect. Cervical disc herniation is unlikely to cause acute severe hypertension or nausea and dizziness and would likely be accompanied by neck tenderness or decreased range of motion. Even if this diagnosis was considered likely, cervical magnetic resonance imaging, and not myelography followed by CT, would be the appropriate imaging test.

IMAGING STUDY AND QUESTIONS

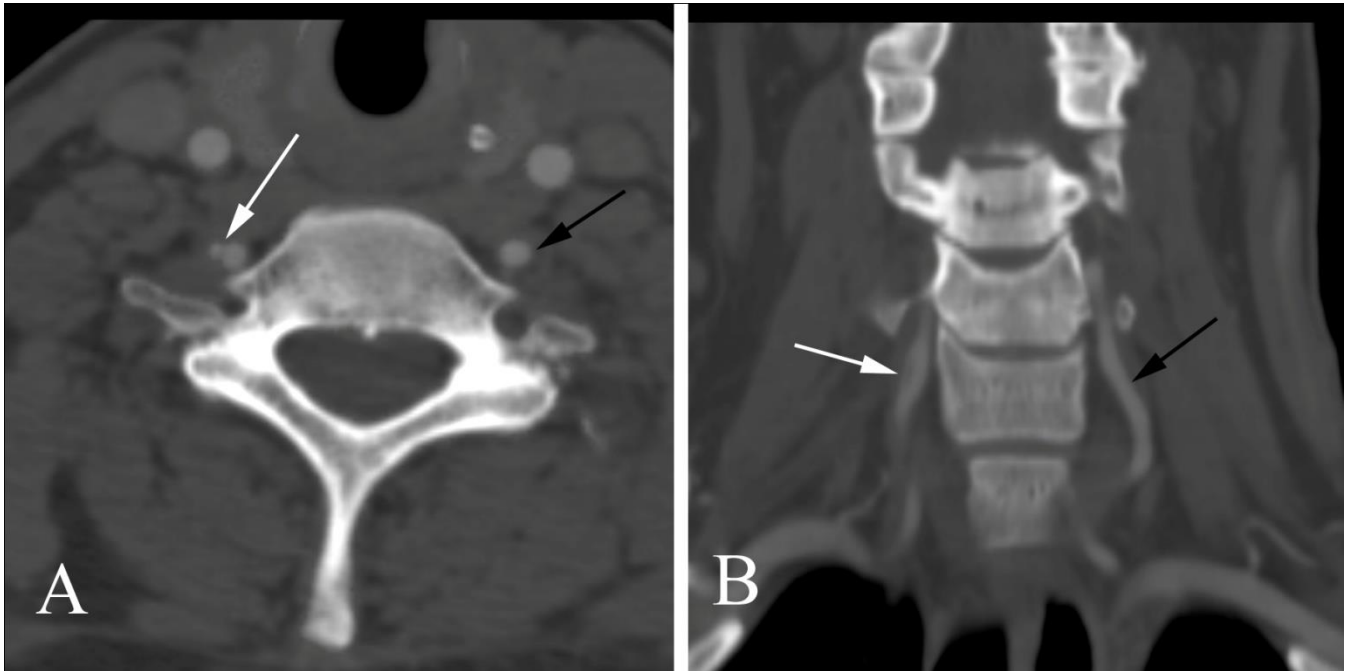
The patient underwent further imaging:



Imaging questions:

- 1) What type of study is shown?
- 2) Are there any abnormalities?
- 3) What is the most likely diagnosis?
- 4) What is the next step in management?

IMAGING STUDY QUESTIONS AND ANSWER



Imaging questions:

- 1) What type of study is shown? A CT angiogram of the cervical vessels.
- 2) Are there any abnormalities? Yes. There is an abnormal appearance of a short segment of the right vertebral artery (white arrow) which is divided into two separate channels. Note the normal appearance of the contralateral, left vertebral artery (black arrow).
- 3) What is the most likely diagnosis? Vertebral artery dissection.
- 4) What is the next step in management? Immediate consultation with neurology, neurosurgery, and/or interventional neuroradiology.

PATIENT DISPOSITION, DIAGNOSIS, AND FOLLOW-UP
--

Emergency consultation with interventional neuroradiology and neurology was obtained. The recommendation on the basis of the diagnosis made on the CT angiography was to anti-coagulate the patient. There was no need reason to acutely intervene in this case, and the patient was placed on anti-coagulants (a Lovenox bridge to Coumadin). The patient's blood pressure was treated with 20 mg IV labetalol, repeated a total of three times to achieve a final level of 150/90.

Cervical arterial dissection accounts for up to 20% of strokes occurring in patients under the age of 50, and should be considered in any young adult with acute neck pain and neurologic symptoms which could be vascular in nature. Blunt trauma and chiropractic manipulation may precede cervical arterial dissection, but many cases are spontaneous with no cause ever found. If the patient does not have a debilitating stroke at the time of the initial dissection, the long-term prognosis is generally good.

SUMMARY

Presenting symptoms: The patient had a combination of symptoms along with acute hypertension, and provided a diagnostic challenge. As noted on page 2, the combination of headache, possible neurologic abnormality (dizziness, nausea), and neck pain without tenderness or loss of motion suggested the diagnosis of cervical arterial dissection.

Imaging work-up: In patients suspected to have cervical arterial dissection, CT angiography and MR angiography are likely equivalent in diagnostic accuracy. CT is usually more readily available, faster to perform, and more compatible with any medical equipment needed in severely ill patients.

Establishing the diagnosis: When there is a classic, typical appearance of arterial dissection on CT angiography and MR angiography, the imaging study establishes the diagnosis. Catheter angiography is considered the reference standard but is usually not necessary when non-interventional imaging studies are diagnostic.

Take-home message: Cervical arterial dissection should be suspected in young adults with acute onset of neck pain without neck tenderness or loss of range of motion and possible vascular-compromise type neurologic symptoms.

FURTHER READING

Dziewas R, Konrad C, Drager B et al. Cervical artery dissection -- clinical features, risk factors, therapy, and outcomes in 126 patients. *J Neurol* 2003;250:1179-1184.

Leys D, Lucas C, Gobert M et al. Cervical artery dissections. *Eur Neurol* 1997;37:3-12.

Provenzale JM, Sarikaya B. Comparison of test performance characteristics of MRI, MR angiography, and CT angiography in the diagnosis of carotid and vertebral artery dissection: a review of the medical literature. *AJR* 2009; 193:1167-1174.