

## CLINICAL PRESENTATION AND RADIOLOGY QUIZ QUESTION

A 60 year old man presents for a second visit regarding mid chest burning and discomfort which radiates into his back. He has a remote history of ulcer disease. At an initial visit, he related that the pain was related to meals and was prescribed lansoprazole. Since the first visit, he has not noted much relief with the medication, and he has been paying more attention to the circumstances of his pain which he now notes to be related to activity. The pain does not bother him at when he is at rest or wake him from sleeping. He describes a “burning sensation” in the front of his chest with no radiation to his jaw or either arm. His blood pressure is 112/76, his pulse 60, and his temperature 98.9 F. A chest radiograph (not shown) was unremarkable.

Which of the following imaging studies is the best next step in the evaluation of this patient?

- (a) left side down decubitus plain film examination
- (b) ultrasound of the chest
- (c) magnetic resonance imaging of the chest
- (d) myocardial perfusion stress test

<b>RADIOLOGY QUIZ QUESTION, ANSWER, AND EXPLANATION</b>
---

A 60 year old man presents for a second visit regarding mid chest burning and discomfort which radiates into his back. He has a remote history of ulcer disease. At an initial visit, he related that the pain was related to meals and was prescribed lansoprazole. Since the first visit, he has not noted much relief with the medication, and he has been paying more attention to the circumstances of his pain which he now notes to be related to activity. The pain does not bother him at when he is at rest or wake him from sleeping. He describes a “burning sensation” in the front of his chest with no radiation to his jaw or either arm. His blood pressure is 112/76, his pulse 60, and his temperature 98.9 F. A chest radiograph (not shown) was unremarkable.

Which of the following imaging studies is the best next step in the evaluation of this patient?

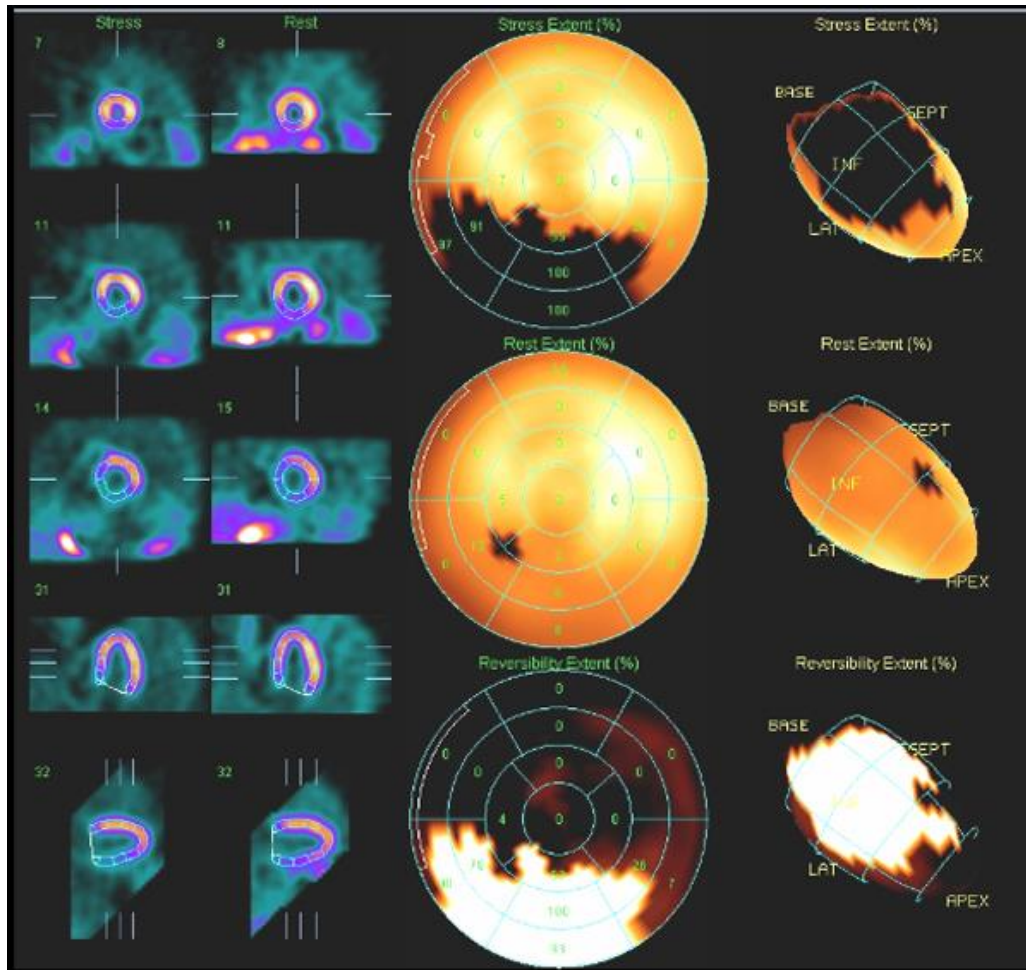
- (a) left side down decubitus plain film examination
- (b) ultrasound of the chest
- (c) magnetic resonance imaging of the chest
- (d) myocardial perfusion stress test

Answer: (d), myocardial perfusion stress test, is the correct response. The two-view chest radiograph was normal. Given the patient’s history of chest pain related to activity and failed trial of lansoprazole, it is reasonable to suspect that he may have a cardiac origin of his pain.

A left-side down decubitus plain film might be helpful in cases where a left pleural effusion or a right pneumothorax was suspected on a supine radiograph, but in this case the upright two-view chest plain film was normal, and (a) is incorrect. Ultrasound of the chest is helpful to evaluate the location and extent of a pleural effusion but the patient has no effusion on the plain film exam, and (b) is incorrect. Magnetic resonance of the chest is rarely performed and is not the standard next step in evaluation of chest pain in the setting of a normal chest radiograph, and (c) is incorrect.

## IMAGING STUDY AND QUESTIONS

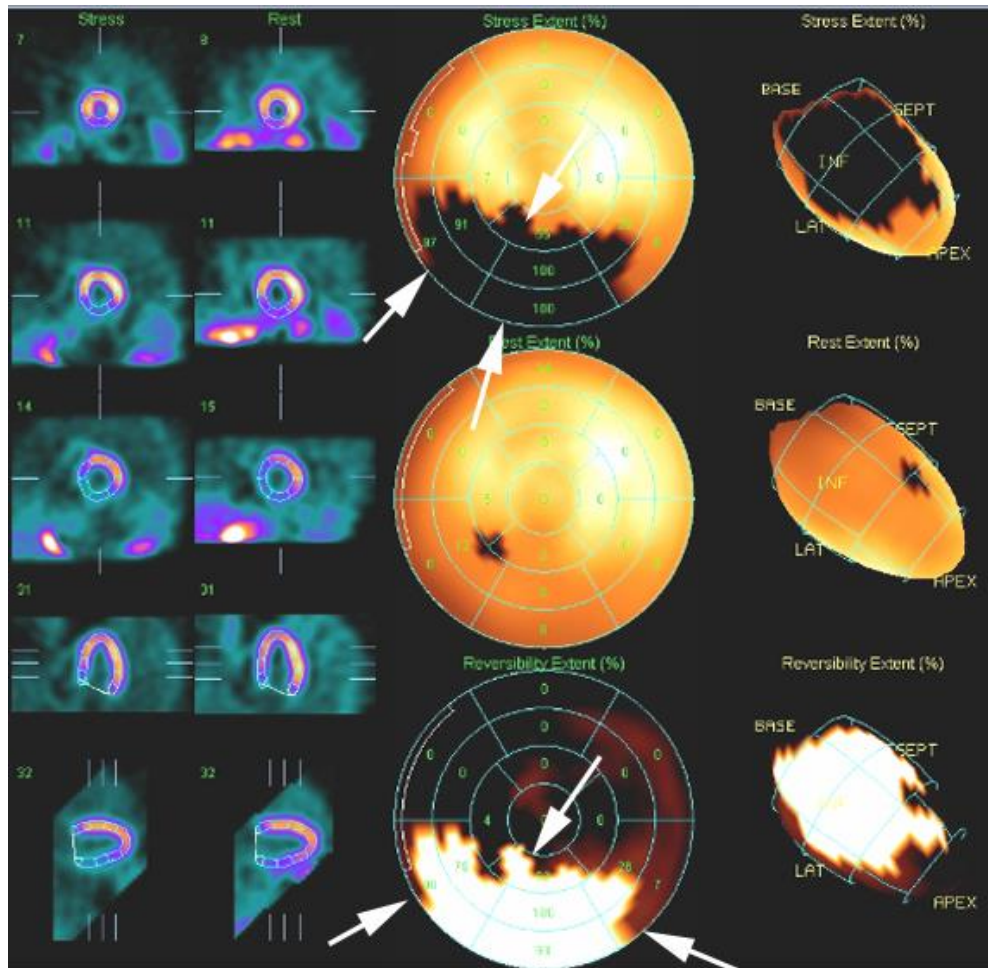
The patient underwent further imaging:



Imaging questions:

- 1) What type of study is shown?
- 2) Are there any abnormalities?
- 3) What is the most likely diagnosis?
- 4) What is the next step in management?

## IMAGING STUDY QUESTIONS AND ANSWER

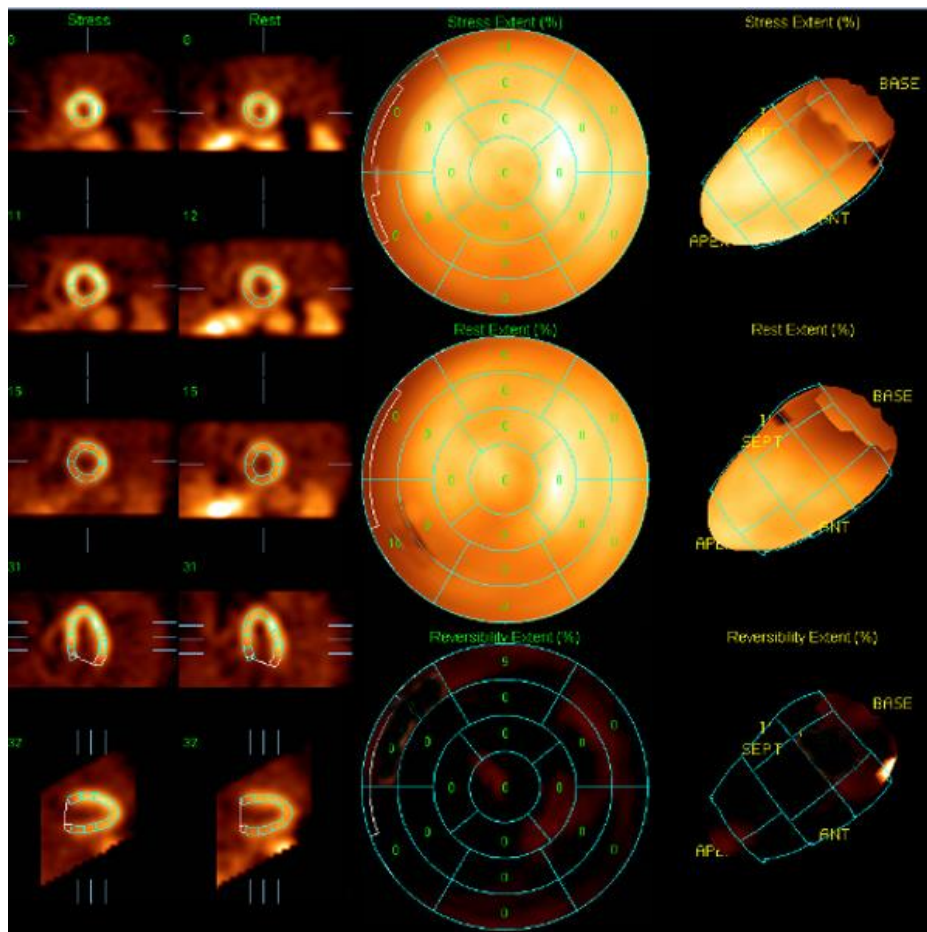


### Imaging questions:

- 1) What type of study is shown? A nuclear medicine myocardial perfusion study.
- 2) Are there any abnormalities? Yes. The stress image (top central image) shows an extensive area of decreased radiotracer localization (arrows). This normalizes on the resting study (middle central image). A subtraction image shows extensive reversible decreased radiotracer localization in the inferior wall and inferior septum of the left ventricle (arrows).
- 3) What is the most likely diagnosis? Reversible ischemic disease of the left ventricular wall myocardium, located in the inferior wall and inferior septum. This area is generally supplied by the right coronary artery.
- 4) What is the next step in management? Referral to cardiology with likely coronary angiography to follow.

## PATIENT DISPOSITION, DIAGNOSIS, AND FOLLOW-UP

The patient was referred to a cardiologist who performed coronary angiography, which showed 95% stenosis of a large, dominant right coronary artery. The cardiologist then performed percutaneous transluminal coronary angioplasty and placed two overlapping stents. The patient did well subsequently with elimination of his activity related “chest burning.” At a follow-up exam four years later the patient brought in a list of requirements that needed to be completed to allow him to drive a motor coach. One of the requirements was a repeat stress test (even though he had no symptoms). This study was normal (see below). The patient continues to do well clinically.



60 y/o white male with a history of prior chest pain relieved following PTCA and right coronary artery stent placement. Stress (top middle panel), resting (mid middle panel) and subtraction (bottom middle panel) are all normal, with no evidence of either fixed or reversible ischemia.

## SUMMARY

**Presenting symptom:** The patient initially presented with chest pain. He had a personal history of ulcer disease and related his chest pain to meals, and so was initially treated with lansoprazole with no imaging performed at the time.

**Imaging work-up:** Since the patient's pain persisted, a chest plain film was obtained, which was negative. Because on the follow-up visit the patient admitted that his pain features were suggestive of myocardial ischemia, he was further evaluated with a myocardial perfusion study. Cardiac stress studies, done either without or with imaging, are helpful in patients with an intermediate risk of myocardial ischemia. This risk is generally based on the patient's personal history of prior cardiac events and characteristics of the patient's pain.

**Establishing the diagnosis:** The myocardial perfusion study in this case indicated reversible myocardial ischemia. However, the purpose of the imaging study is generally to sort out those patients who require further evaluation for coronary angiography (which is the reference standard for coronary artery disease) and those who do not (and likely have an alternative explanation for their chest pain). In this case, the coronary angiography confirmed right coronary artery stenosis.

**Take-home message:** When imaging is performed in ambulatory patients with chest pain, the initial study should be an upright, two-view chest radiograph. If coronary artery disease is suspected with an intermediate (between approximately 25% and 75%) likelihood, stress testing with or without imaging is a reasonable next step in evaluation. This likelihood is estimated based on the patient's pain pattern, age, and sex. Adding imaging to the stress test increases the sensitivity of the examination by about 20%.

### FURTHER READING

Garber AM, Hlatky MA. Stress testing for the diagnosis of coronary artery disease. UpToDate, accessed 10/7/09.

Meisel JL. Diagnostic approach to chest pain in adults. UpToDate, accessed 10/2/09.

Papaioannou GI, Heller GV. Exercise radionuclide myocardial perfusion imaging in the diagnosis and prognosis of coronary heart disease. UpToDate, accessed 10/8/09.

Renfrew, DL. Imaging of chest pain. Chapter 11 of *Symptom Based Radiology*, Symptom Based Radiology Publishing, Sturgeon Bay, WI, 2010, available for no charge at [www.symptombasedradiology.com](http://www.symptombasedradiology.com).